

TRACHEOSTOMY AND ITS VARIANTS

Dr. Praveen Kumar Neema¹ Dr. Sethuraman Manikandan²

Introduction

Placement of a tracheostomy tube percutaneously is not a new idea; pictures of devices that appear to have been developed for this purpose date back to the Rigveda.¹ A modern percutaneous tracheostomy (PCT) device was developed by Toye and Weinstein in 1969, and its use in 100 trauma patients was reported in 1986.^{2,3} The wire-guided technique for percutaneous tracheostomy was developed and reported in the same year by the American surgeon, Ciaglia.⁴ Primary or secondary respiratory failure is common in the intensive care unit, especially in patients with multiorgan failure that results in prolonged ventilatory support. A consensus conference of the National Association of Medical Directors of Respiratory care recommended that tracheostomy should be performed when the ventilatory support is anticipated to be more than 21 days.⁵ Ever since the PCT has evolved, the resources required for a surgical tracheostomy (ST), the needs of operating room, and personnel are eliminated. This article reviews the indications, contraindications, equipments and procedure of percutaneous tracheostomy. The details of ST are not described as it is generally performed by the surgeons.

Indications

1. Upper Airway obstruction secondary to - trauma, burns and corrosive poisoning, laryngeal dysfunction, foreign body, infections, inflammatory conditions, neoplasms, postoperative, obstructive sleep apnea
2. Access for pulmonary toilet
3. Prolonged ventilatory support
4. Airway protection in head injured or comatose patient and in postoperative neurosurgical patients

Contraindications

Absolute

1. Need for an emergency airway
2. Performance of the procedure in children as cartilages is soft.

1. M.D., Asso. Prof.
2. M.D., Asst. Prof.
Sree Chitra Tirunal Institute for Medical Sciences and Technology, Trivandrum, Kerala.

Correspond to :

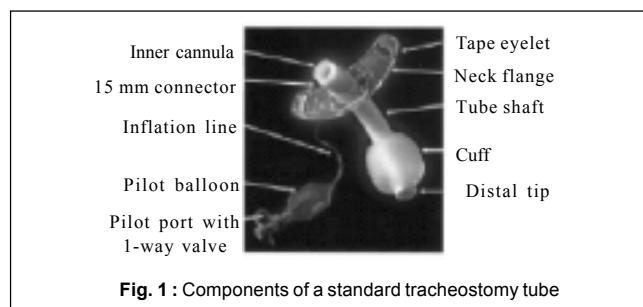
Dr. P. K. Neema
E-mail : praveenneema@hotmail.com

Relative

1. High degree of ventilatory support—PEEP >8cm H₂O, FiO₂ > 50%
2. Unstable cervical spine
3. Uncorrected coagulopathy
4. Presence of neck mass or previous neck surgery
5. History of mediastinal irradiation due to intrathoracic fibrosis
6. Previous history of surgical tracheostomy
7. Increased intracranial pressure

Tracheostomy appliances

Tracheostomy tubes (fig. 1) are available in a variety of sizes and styles, from several manufacturers. The dimensions of tracheostomy tubes are given by their inner diameter (ID), outer diameter (OD), length, and curvature.⁶ Tracheostomy tubes can be angled or curved, a feature that can be used to improve the fit of the tube in the trachea. Differences in length exist between tubes of the same ID. Extra proximal length tubes facilitate placement in patients with large necks, and extra distal length tubes facilitate placement in patients with tracheal anomalies. Cuffs on tracheostomy tubes include high-volume low-pressure cuffs, tight-to shaft cuffs, and foam cuffs. Tracheostomy tubes with an inner cannula are called dual cannula tracheostomy tubes. Several tracheostomy tubes are designed specifically for use with the percutaneous tracheostomy procedure. Others are designed with a port above the cuff that allows for subglottic aspiration of secretions.⁶ The tracheostomy button is used for stoma maintenance.



Metal versus Plastic tracheostomy tubes

Tracheostomy tubes can be of either metal or plastic.⁶ Metal tubes (fig. 2) are constructed of silver or stainless steel. Metal tubes are not used commonly because of their expense, their rigid construction, the lack of a cuff, and the lack of a 15 mm connector to attach a ventilator. A smooth

rounded tip obturator passed through the lumen of the tracheostomy tube facilitates insertion of the tube. The obturator is removed once the tube is in place. The Jackson size (table 1) describes the sizes of some tubes and refers to the length and taper of the OD. Plastic tubes are most commonly used and are made from polyvinyl chloride or silicone. Polyvinyl chloride softens at body temperature (thermolabile), conforming to patient's tracheal anatomy and centering the distal tip in the trachea.

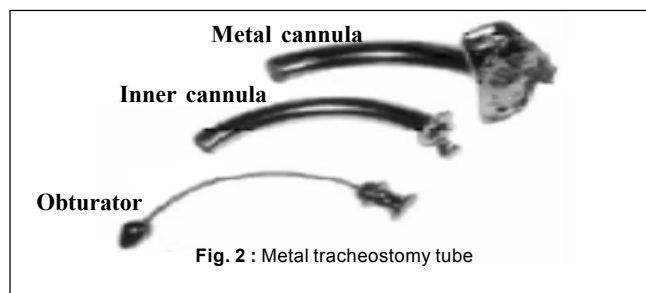


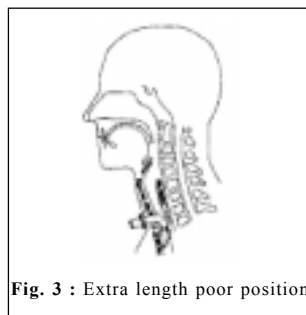
Table - 1 : Jackson tracheostomy tube size.

Jackson size	ID with IC (mm)	ID without IC (mm)†	Outer diameter (mm)
4	5	6.7	9.4
6	6.4	8.1	10.8
8	7.6	9.1	12.2
10	8.9	10.7	13.8

† Inner diameter is for the narrowest portion of the shaft IC – Inner cannula

Tracheostomy tube selection

While selecting a tracheostomy tube, the ID and OD, its curvature and proximal and distal length must be considered. If the ID is too small, it will increase the resistance through the tube, make airway clearance difficult, and increase the cuff pressure required to create a seal in the trachea. If the OD is too large, leak with the cuff deflated will be decreased, and this will affect the ability to use the upper airway with cuff deflation (eg, speech). A tube with a larger OD will also be more difficult to pass through the stoma. The curved tube may not conform to the shape of the trachea, potentially allowing for compression of the membranous part of the trachea, while the tip may traumatize the anterior portion. If the curved tube is too short, it can obstruct against the posterior tracheal wall that can be remedied by using either a larger tube, an angled tube, a tube with a flexible shaft, or a tube with extra length. Because the portion of the tube that extends into the trachea is straight and conforms more closely to the natural anatomy of the airway, the angled tube may be better centered in the trachea and cause less pressure along the tracheal wall. Tracheostomy tubes are available in



standard length or extra length. Extra length tubes are constructed with extra proximal length (horizontal extra length) or with extra distal length (vertical extra length). Extra proximal length facilitates tracheostomy tube placement in patients with a large neck (eg, obese patients). Extra distal length facilitates placement in patients with tracheal malacia or tracheal anomalies. Care must be taken to avoid inappropriate use of these tubes, which may induce distal obstruction of the tube (fig. 3). Differences in tracheostomy tube length between tubes of the same ID but from different manufacturers are not commonly appreciated and this can have important clinical implications.⁶

Tracheostomy tube cuffs

Tracheostomy tubes can be cuffed or uncuffed. Cuffed tracheostomy tubes allow airway clearance, offer some protection from aspiration and positive pressure ventilation, can be more effectively applied when the cuff is inflated. Although cuffed tubes are generally considered necessary to provide effective positive pressure ventilation, a cuffless tube can be used effectively in long-term mechanically ventilated patients with adequate pulmonary compliance and sufficient oropharyngeal muscle strength for functional swallowing and articulation.⁷ It is recommended that cuff pressure be maintained at 20–25 mmHg (25–35 cm H₂O) to minimize the risks for both tracheal wall injury and aspiration. A leak around the cuff is assessed by auscultation over the suprasternal notch or the lateral neck. Techniques such as the minimum occlusion pressure or the minimum leak technique is not recommended. In particular, the minimum leak technique is not recommended because of the risk of silent aspiration of pharyngeal secretions.⁶

Fenestrated tracheostomy tubes

The fenestrated tracheostomy tube is similar in construction to standard tracheostomy tubes, with the addition of an opening in the posterior portion of the tube above the cuff. With the inner cannula removed, the cuff deflated, and the tracheostomy air passage occluded, the patient can inhale and exhale through the fenestration and around the tube. This allows for assessment of the patient's ability to breathe through the normal oral/nasal route (preparing the patient for decannulation) and permits air to pass by the vocal cords (allowing phonation). Supplemental oxygen administration to the upper airway (eg, nasal cannula) may be necessary if the tube is capped. The cuff must be

completely deflated by evacuating all of the air before the tube is capped. The decannulation cap is then put in place to allow the patient to breathe through the fenestrations and around the tube.

Percutaneous tracheostomy tubes

Several tracheostomy tubes are designed specifically for insertion as part of the percutaneous dilatational tracheostomy procedure.⁶ The Portex Per-fit flexible tube features a tapered distal tip and a low-profile cuff designed to reduce insertion force and more readily conform to the patient's tracheal anatomy. The cuff characteristics resemble those of a low-volume high-pressure cuff. The Shiley PERC tracheostomy tube has a tapered distal tip and inverted cuff shoulder for easier insertion. It is designed specifically to be used with the Cook Percutaneous Tracheostomy Introducer Set. This cuff provides a low-pressure seal. Trottier et al reported significant obstruction with a Portex Per-Fit tracheostomy tube placed percutaneously.⁸ The cause of the partial obstruction was the membranous posterior tracheal wall encroaching on the tracheostomy tube lumen. Several patients displayed a dynamic component to the obstruction, such that when the patient's intrathoracic pressure increased, the degree of obstruction also increased. One patient displayed clinical signs and symptoms of tracheostomy tube obstruction. This patient was obese and had a large neck, such that the tracheostomy tube was too short for the patient. These findings prompted the investigators to recommend modifications to the tube to lessen the degree of partial tracheostomy tube obstruction. The standard tracheostomy tube was modified to include a shortened posterior bevel (the longest portion of the tracheostomy tube posteriorly) and a decreased length and angle of the tracheostomy tube. Following this modification, 25% tube obstruction was observed in only 1 of 17 patients.

Mini-tracheostomy tubes

The mini-tracheostomy tube is a small bore cannula (4.0 mm ID) inserted into the trachea through the cricothyroid membrane or the tracheal stoma after decannulation. It can be used for administration of oxygen. However, it is used primarily for patients with airway clearance issues because it allows bronchial lavage and suctioning with a 10 Fr suction catheter. It is uncuffed and generally unsuitable for provision of positive pressure ventilation.⁶

Techniques for performing PCT

The wire-guided technique for percutaneous tracheostomy was developed and reported in 1986 by the American surgeon, Ciaglia, who combined the Seldinger wire, nephrostomy tube, multiple-dilator placement technique, with a special, low-profile tracheostomy tube.⁴

Several variants of the percutaneous tracheostomy technique have been developed, including a wire guided sharp forceps (Griggs technique);⁹ performance of the procedure under bronchoscopic control, using a single tapered dilator (Blue Rhino);¹⁰ passing the dilator from inside the trachea to the outside (Fantoni's technique);¹¹ and using a screw like device to open the trachea wall (PercTwist).¹² Each of these variations came about in an attempt to improve some aspect of another technique.

Percutaneous dilational tracheostomy (PDT)

PDT has become a very common method of placing a tracheostomy in critically ill patients in the intensive care unit. It is rapid, simple, easy to learn, and cost effective. While it is superior to ST, it has some important problems such as hemorrhage, unsuitability in emergencies and in patients needing high level of respiratory support. Long-term problems include scar development, tracheal cutaneous fistula, and tracheal stenosis. Whether prophylactic antibiotics are useful for PDT is not yet known; however, one report suggests that they should be used and be tailored to the known flora of the tracheobronchial tree. The procedure should be deferred in patients having an INR > 1.4, activated partial thromboplastin time > 45 seconds, and platelet count of < 75,000 ml⁻¹. While some clinicians continue to perform PDT blindly, most have adopted a technique of observing and directing the needle and wire placement, using fiberoptic bronchoscopy.¹³ This may help prevent inadvertent injury of the membranous posterior tracheal wall or too lateral a location of the tracheostomy.¹⁴ In order to visualize the upper rings of the trachea with the bronchoscope, the endotracheal tube (ET) must be withdrawn until the its tip is just in the larynx. This creates a substantial leak, as the cuff is no longer in the trachea. Patients experiencing severe hypoxic respiratory failure may deteriorate during this period and may benefit from conversion to ST rather than persistence with PDT.¹ Patients requiring a tracheostomy only for airway access or protection often can have a laryngeal mask airway replace the endotracheal tube to provide the route for bronchoscopic visualization. The view of the larynx is unhampered when performed this way, making accurate identification of the tracheal rings easy. Moreover, bronchoscopy through a laryngeal mask airway often reveals important pathology of the vocal cords. The patient should receive 100% O₂ for 10 min before the procedure. As with placement of an ST, a PDT is usually performed in an anesthetized patient, and can be done in the intensive care unit or operating room. The patient should be monitored by SpO₂, EtCO₂ and ECG. The patient is positioned as for the surgical tracheostomy, a pillow is placed under the shoulders, the neck is moderately extended, and the first three tracheal rings are identified.

If the tracheal rings are not palpable then a point between the cricoid cartilage and the suprasternal notch is marked. The anterior neck is prepared with povidine iodine and draped with sterile sheets. The skin overlying first and second tracheal rings is infiltrated subcutaneously with 3-5 ml of 1% xylocaine with epinephrine (1:200,000), and a 1.5 cm vertical incision is made and blunt dissection is performed to expose the pretracheal fascia. The anterior trachea is palpated and the intended site is punctured with a 14G intravenous cannula in a postero-caudal direction. The entry of the IV cannula in trachea is confirmed by aspiration of air into a saline filled syringe (fig. 4). A guide wire is inserted through the cannula, and the cannula is withdrawn, thereafter, the tracheal opening is dilated over the guide wire until a stoma of sufficient size to accommodate the desired tracheostomy tube is created (fig. 5). The method of dilating the tracheal opening over

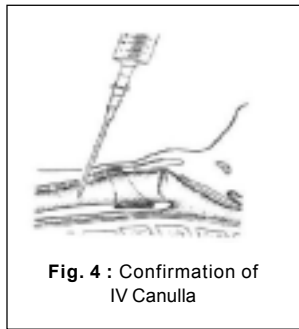


Fig. 4 : Confirmation of IV Canulla




Fig. 5 : The guide wire is threaded through the catheter to act as a guid for the dilating forceps

the guide wire varies with various methods. With Ciaglia technique, the tracheal opening is dilated by using (fig. 6a) a series of plastic dilators inserted over the guide wire. An alternative to the sequential dilator technique was developed by Griggs et al⁹ (fig. 6 b, c). Using a tracheal spreader (fig. 7) modified to thread over the wire; this technique involves forceps dilation to create the skin path and tracheal




Fig. 6a : Dilators used for ciaglia method

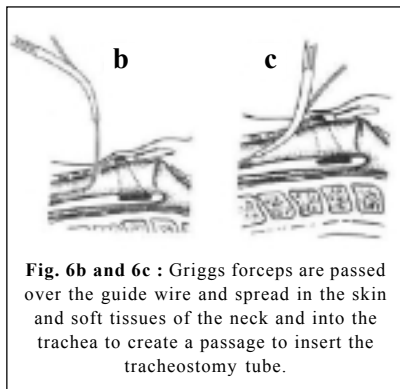


Fig. 6b and 6c : Griggs forceps are passed over the guide wire and spread in the skin and soft tissues of the neck and into the trachea to create a passage to insert the tracheostomy tube.

stoma. As with the Ciaglia technique, the trachea is entered between the appropriate tracheal rings with an intravenous catheter. The guide wire is threaded through the catheter.

The sharp-tipped dilating forceps are passed over the wire, spread in the skin and soft tissues of the neck and into the trachea, and spread again. A tracheostomy tube is placed over the guide wire and through the passage created. Tracheal injury may be higher with this technique (especially if performed without bronchoscopy) than the other PDT techniques. The Blue Rhino dilator (fig. 6d) is a single, tapered dilator that is used instead of the sequential dilators of Ciaglia.¹⁰ It has a slippery coating that makes insertion very easy. It is softer and therefore (probably) less likely to



Fig. 6d : The Blue Rhino

damage the membranous tracheal wall. Since there is only a single dilator to pass, insertion is more rapid. A substantial amount of force is needed to insert the dilators and tracheostomy tube, which often collapses the trachea and fractures a tracheal ring. The importance of tracheal ring fracture is not known. In an attempt to prevent membranous tracheal (posterior) wall injury and protect the anterior




Fig. 6e : The Perc Twist

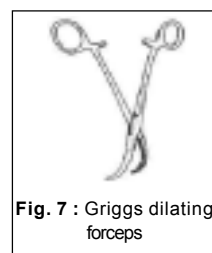

Fig. 7 : Griggs dilating forceps

rings from fracture, Fantoni¹¹ devised a special dilating tube that is placed translaryngeally through the trachea and pulled out rather than forced in. The techniques, is complicated and there are mixed reports regarding its success at protecting the trachea. Another attempt to solve the excessive force problem with PDT is the Perc

Twist (fig. 6e), a screw action dilator that was designed to allow dilation with twisting while lifting the trachea rather than pushing down.¹²

Choosing a technique

The determining factors in deciding whether to use an ST or PDT in a particular situation include available resources (availability of experienced clinicians for either technique) and patient factors. While there are no hard and fast rules, the presence of relative contraindications described in the beginning of this article would favor surgical tracheostomy over PDT.

Tracheostomy and weaning

Current research is focused on the optimal timing of performing a tracheostomy. For patients requiring prolonged mechanical ventilation, performing an early tracheostomy (within 2 days) is considered to facilitate early weaning

from the ventilator. The reasons include reduced dead space. The dead space of a tracheostomy tube with ID 8.5 is 5 ml compared to ETT of similar size which is 24 ml.¹⁵ Other advantages of an early tracheostomy include decreased airway resistance, decreased work of breathing, better secretion clearance by suctioning, more comfortable patient with reduced requirements of sedatives and muscle relaxants, better glottic function with reduced risk of aspiration, atelectasis and pneumonia and shortened ICU stay.¹⁵

Changing the tracheostomy tube

Occasionally a tracheostomy tube must be changed (eg, if the cuff is ruptured or if a different style of tube is needed). The need for routine tracheostomy tube changes is unclear. In an observational study, Yaremchuk, reported fewer complications due to granulation tissue after implementation of a policy in which tracheostomy tubes were changed every 2 weeks.¹⁶ Changing the tracheostomy tube is usually straightforward once the stoma is well formed, which may require 7-10 days after the tracheostomy is first placed. If the tube must be changed before the stoma is well formed, it is advisable that the physician who performed the initial placement perform the tracheostomy tube change. In these cases, it is also important that an individual, skilled in endotracheal intubation is available in the event that the tracheostomy tube cannot be replaced. Generally, it is easier to replace the tube with one that has a smaller OD. The new tracheostomy tube can usually be inserted using the obturator packaged with the tube. If difficulty is anticipated during a tracheostomy tube change, a tube changer can be used to facilitate this procedure. The tube changer is passed through the tube into the trachea.

Complications of PCT

Complications	No. of cases	Percent of total outcome
Tracheal stenosis	21	1.85
Hemorrhage	9	0.87
Tracheocutaneous fistula	6	0.53
Infection	5	0.44
Pneumothorax	3	0.26
Tube decannulation / obstruction	1	0.08
Subcutaneous emphysema	1	0.08
Tracheoesophageal fistula	1	0.08

A recent series of 1,130 patients (table 2) who underwent tracheostomy had a combined procedural, early, and late complication rate of approximately 4%, which is an improvement from the earlier complication rate.¹⁷ In the recent series, tracheal stenosis overtook hemorrhage as the leading complication, by 2 to 1. Tracheal stenosis accounted for nearly half of the complications. Half of the tracheal stenosis required surgical correction. All the patients who developed tracheal stenosis had endotracheal tubes for >12 days before tracheostomy.

References

1. Durbin Jr C G. Techniques for Performing Tracheostomy. *Respir Care* 2005; 50(4): 488-496.
2. Toy FJ, Weinstein JD. A percutaneous tracheostomy device. *Surgery* 1969; 65: 384-389.
3. Toy FJ, Weinstein JD. Clinical experience with percutaneous tracheostomy and cricothyroidotomy in 100 trauma patients. *J Trauma* 1986; 26: 1034-1040.
4. Ciaglia P, Firsching R, Syniec C. Elective percutaneous dilatational tracheostomy: a new simple bedside procedure; preliminary report. *Chest* 1985; 87: 715-719.
5. Rogers S, Puyana JC. Bedside percutaneous tracheostomy in the critically ill patients. *Int Anesth Clinics* 2000; 38: 95-110.
6. Hess DR. Tracheostomy tubes and related appliances. *Respir Care* 2005; 50(4): 497-510.
7. Bach JR, Alba AS. Tracheostomy ventilation: a study of efficacy with deflated cuffs and cuffless tubes. *Chest* 1990; 97(3): 679-683.
8. Trottier SJ, Ritter S, Lakshmanan R, Sakabu SA, Troop BR. Percutaneous tracheostomy tube obstruction: warning. *Chest* 2002; 122(4): 1377-1381.
9. Griggs WM, Worthley LI, Gilligan JE, Thomas PD, Myburg JA. A simple percutaneous tracheostomy technique. *Surg Gynecol Obstet* 1990; 170(6): 543-545.
10. Ambesh SP, Pandey CK, Srivastava S, Agarwal A, Singh DK. Percutaneous tracheostomy with single dilatation technique: a prospective, randomized comparison of Ciaglia Blue Rhino versus Griggs' guidewire dilating forceps. *Anesth Analg* 2002; 95(6): 1739-45.
11. Fantoni A, Ripamonti D. A non-derivative, non-surgical tracheostomy: the translaryngeal method. *Intensive Care Med* 1997; 23(4): 386-392.
12. Westphal K, Maeser D, Scheiffler G, Lischke V, Byhahn C. Percu Twist: a new single-dilator technique for percutaneous tracheostomy. *Anesth Analg* 2003; 96(1): 229-232.
13. Oberwalder M, Weis H, Nehoda H, Kafka-Ritsch R, Bonatti H, Prommegger R et al. Videobronchoscopic guidance makes percutaneous dilatational tracheostomy safer. *Surg Endosc* 2004; 18(5): 839-842.
14. Fernandez L, Norwood S, Roettger R, Gass D, Wilkins H. Bedside percutaneous tracheostomy with bronchoscopic guidance in critically ill patients. *Arch Surg* 1996; 131(2): 129-132.
15. Pierson DJ. Tracheostomy and Weaning. *Respir Care* 2005; 50(4): 526-533.
16. Yaremchuk K. Regular tracheostomy tube changes to prevent formation of granulation tissue. *Laryngoscope* 2003; 113(1): 1-10.
17. Goldenberg D, Ari EG, Golz A, Danino J, Netzer A, Joachims HZ. Tracheostomy complications: a retrospective study of 1130 cases. *Otolaryngol Head Neck Surg* 2000; 123(4): 495-500.