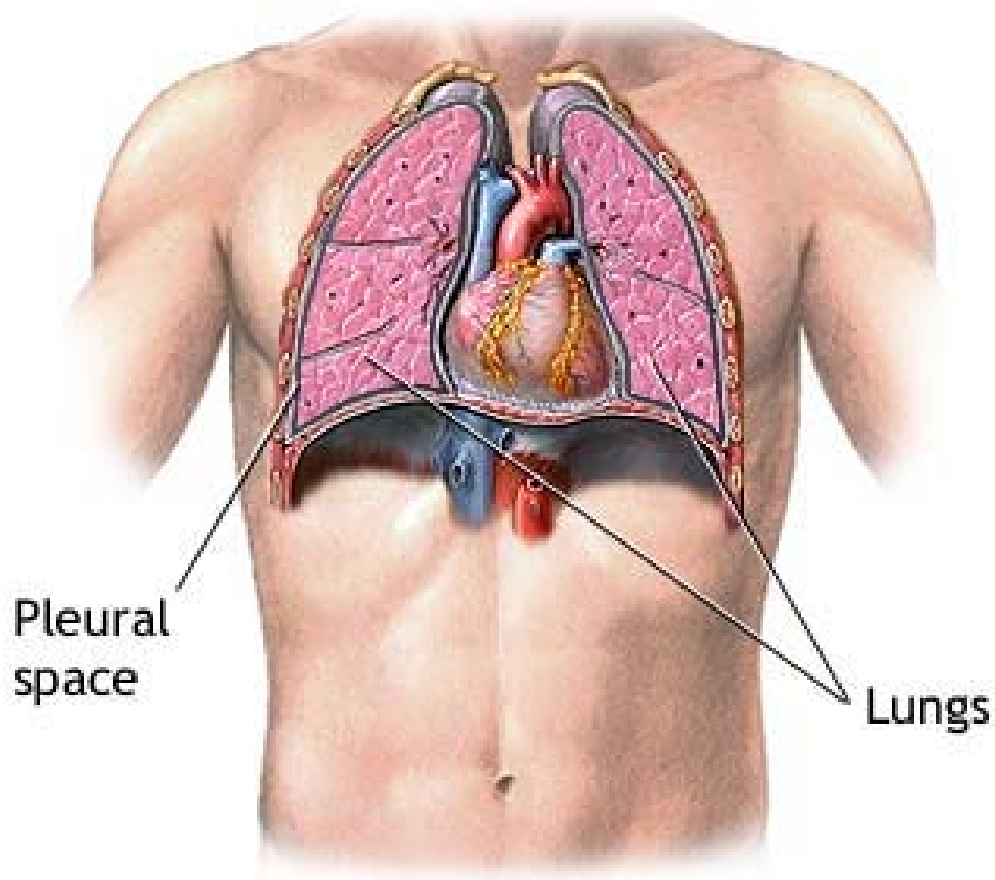


Pneumotorace

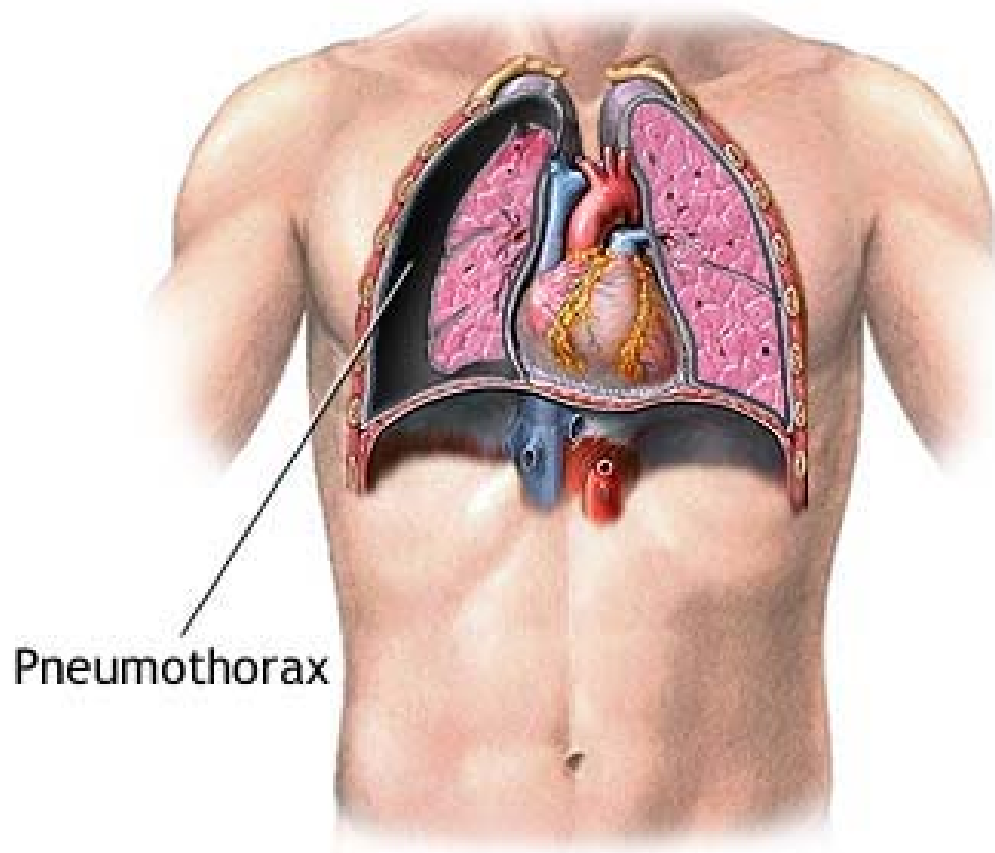
Pneumotorace spontaneo

Anatomia normale



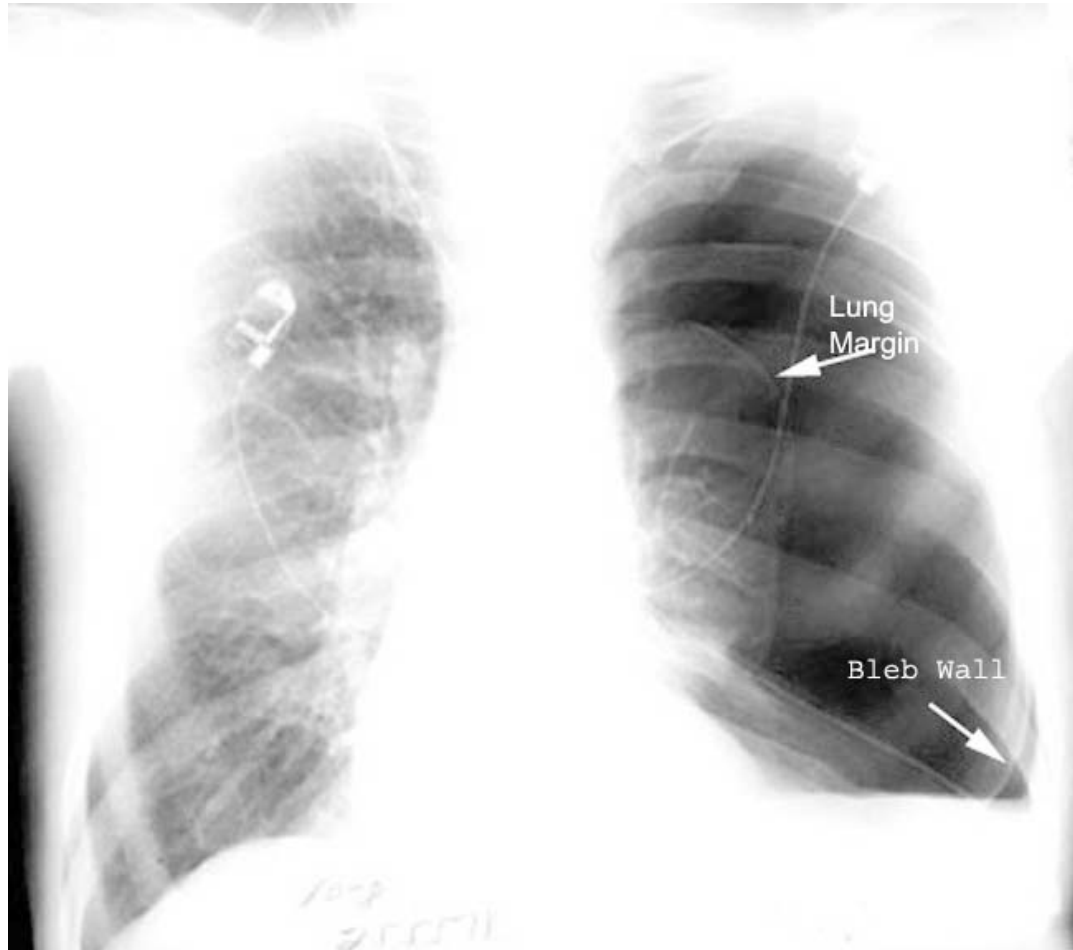
 ADAM.

Pneumotorace destro-presenza di aria nel cavo pleurico destro

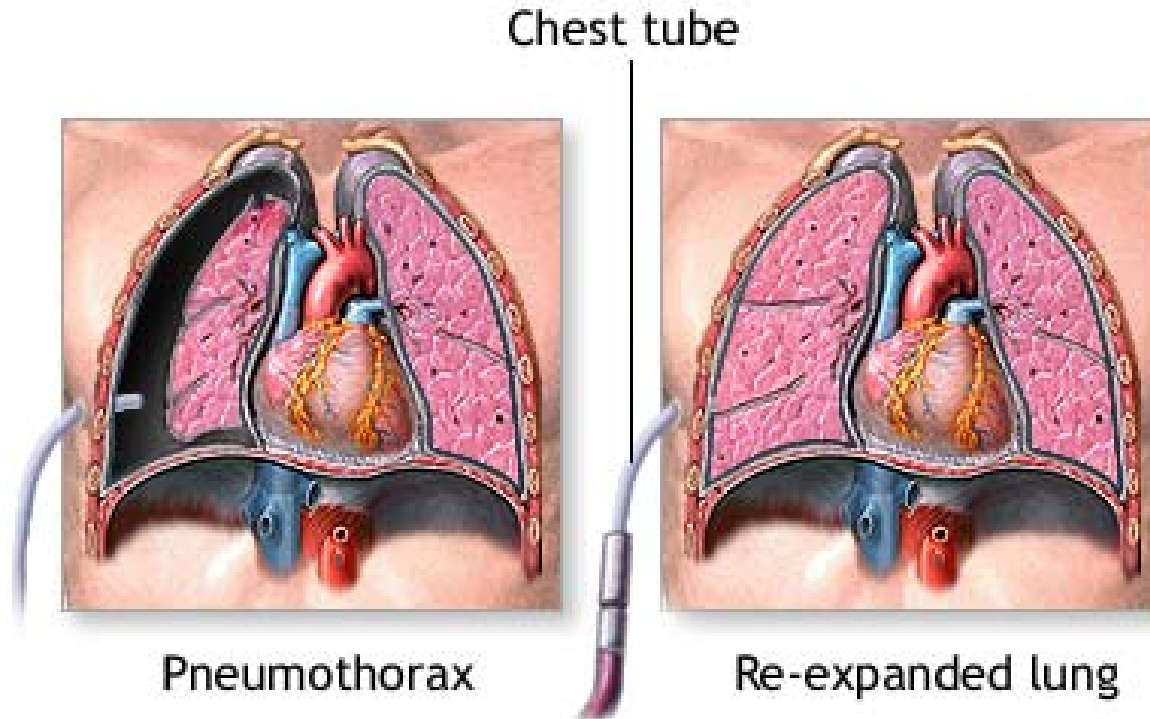


ADAM.

Pneumotorace sinistro

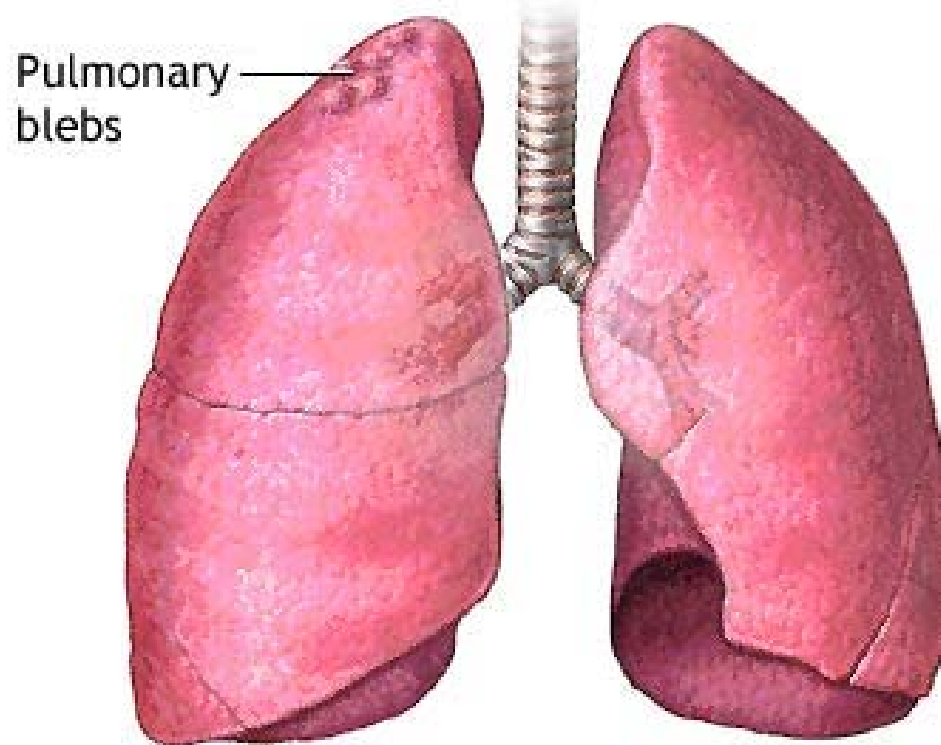


Terapia immediata-Drenaggio pleurico destro



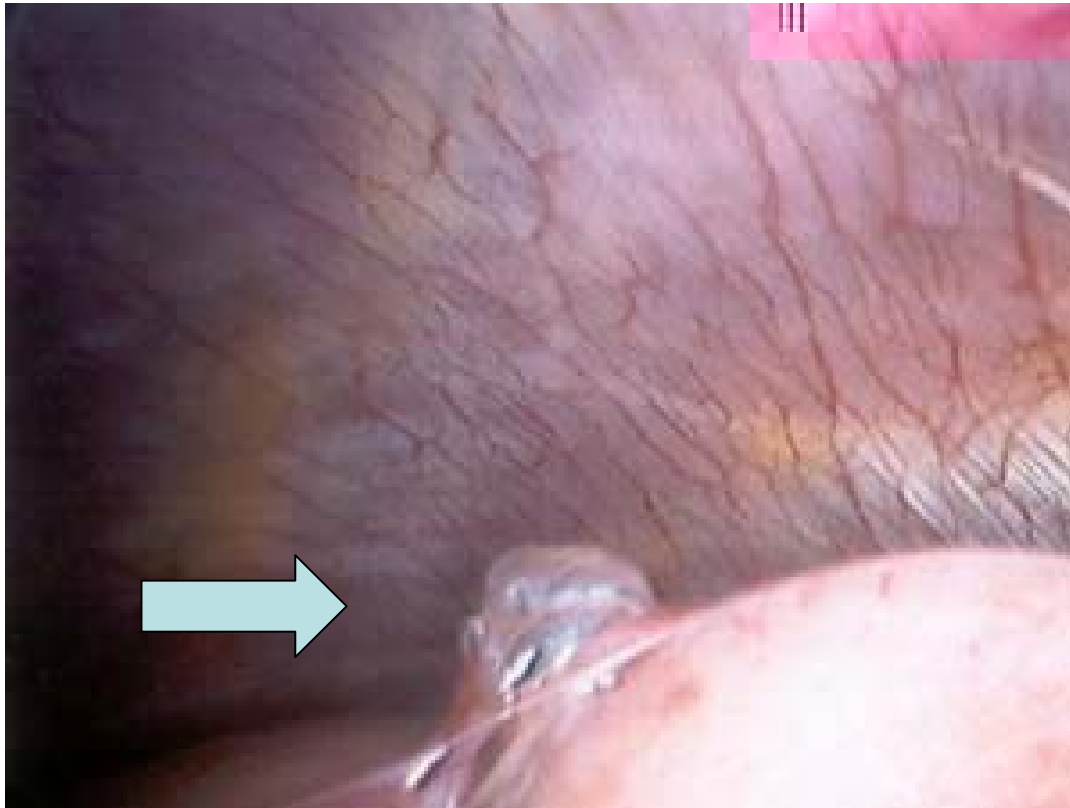
ADAM.

Possibile causa-Blebs apice destro

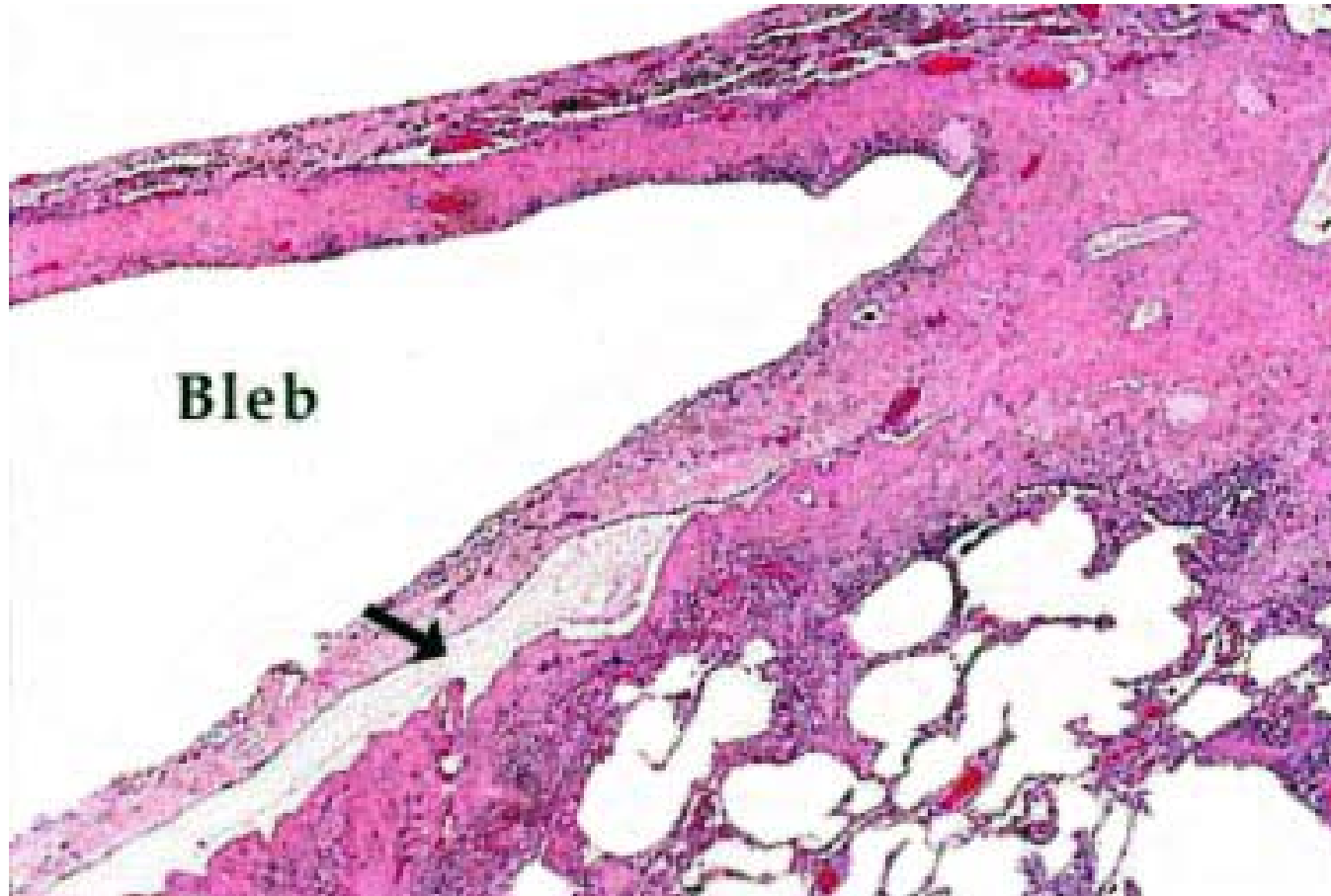


ADAM.

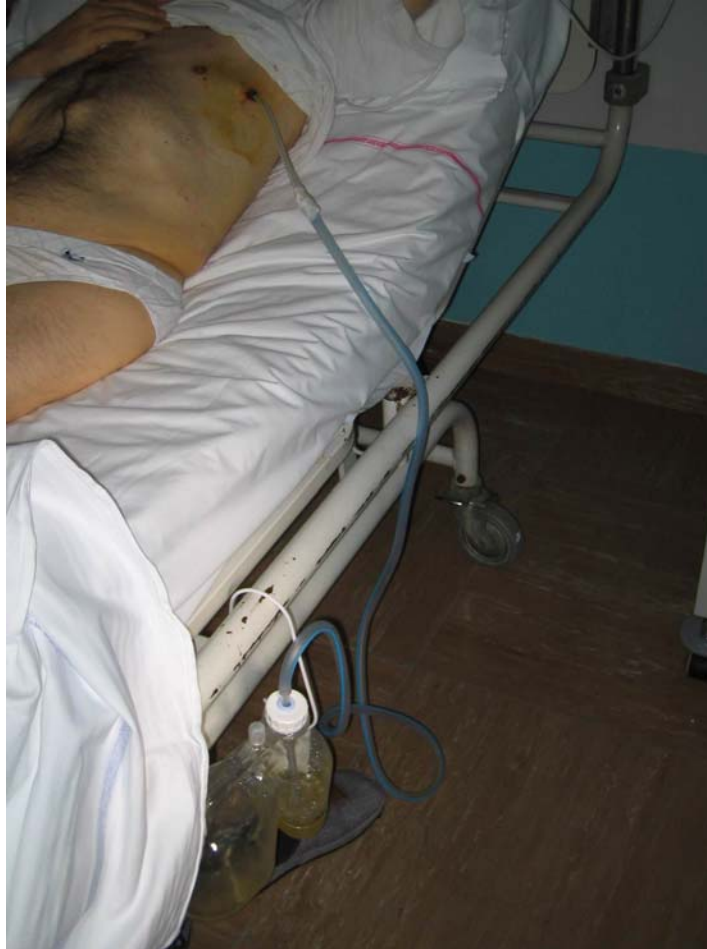bleb



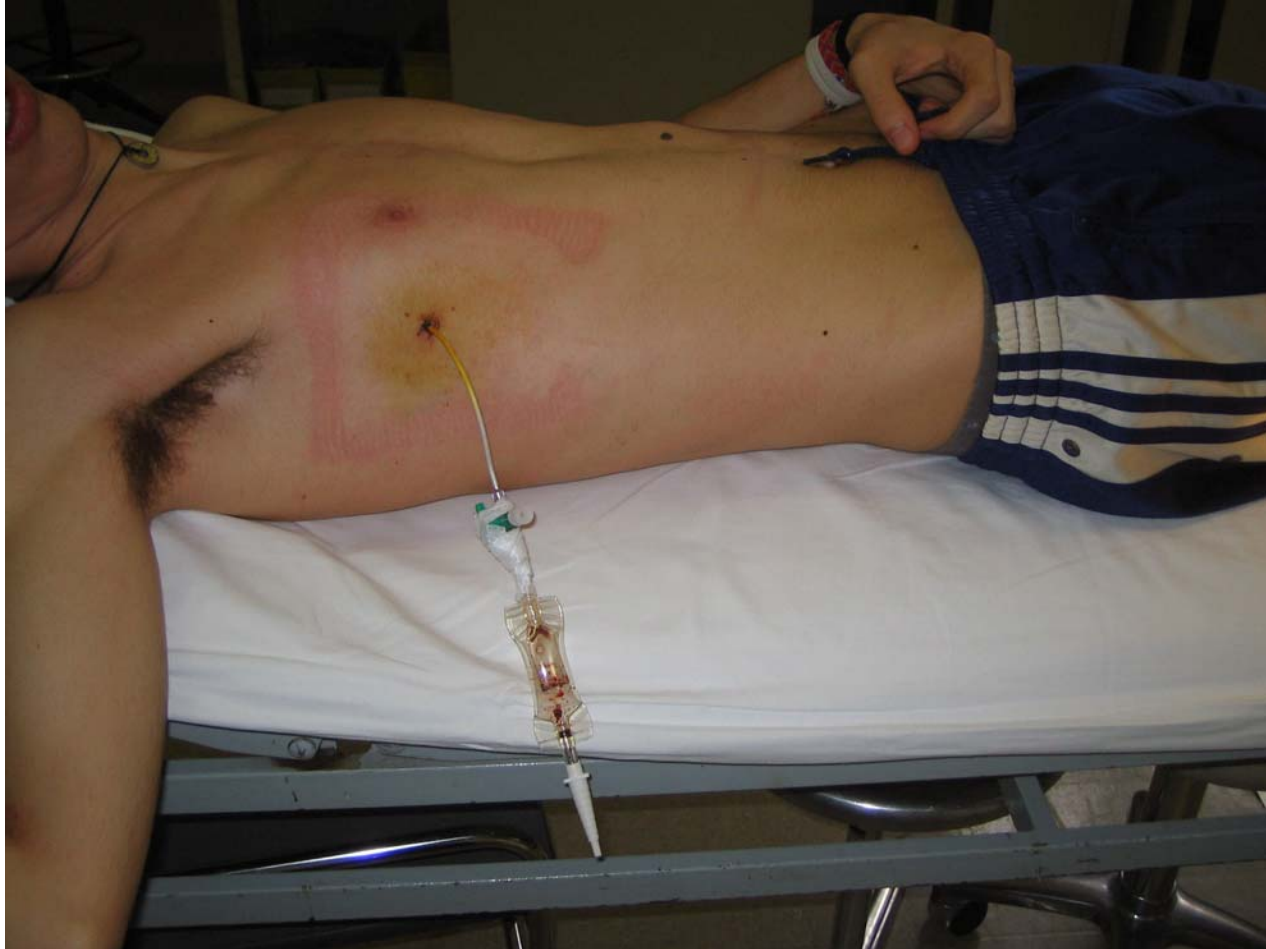Bleb-istologia



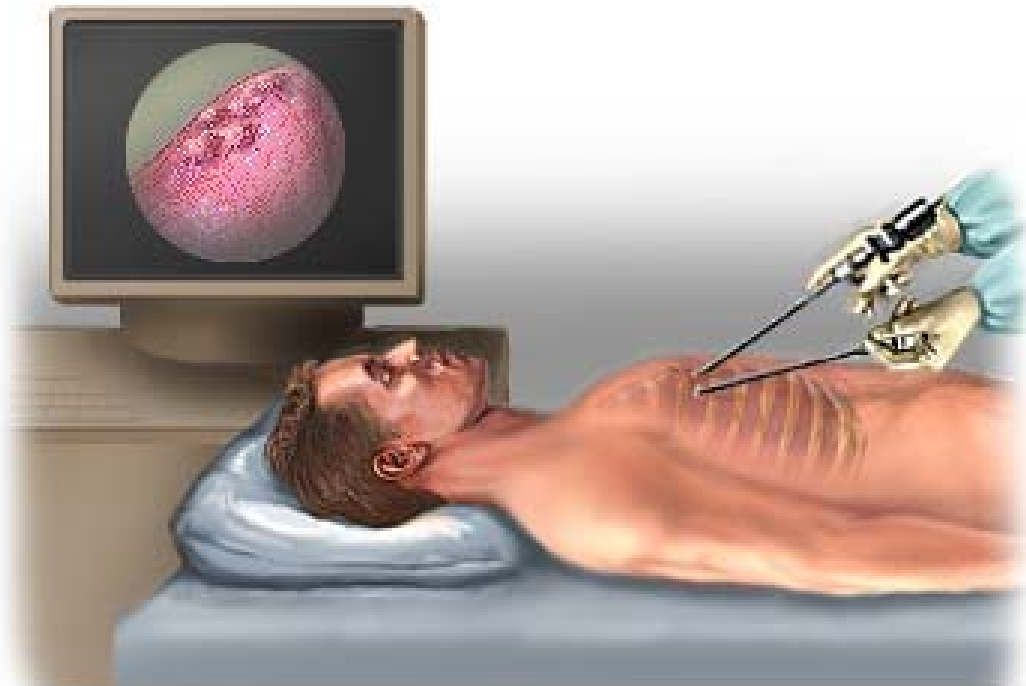
Gestione ospedaliera del drenaggio



Gestione ambulatoriale-domiciliare del drenaggio

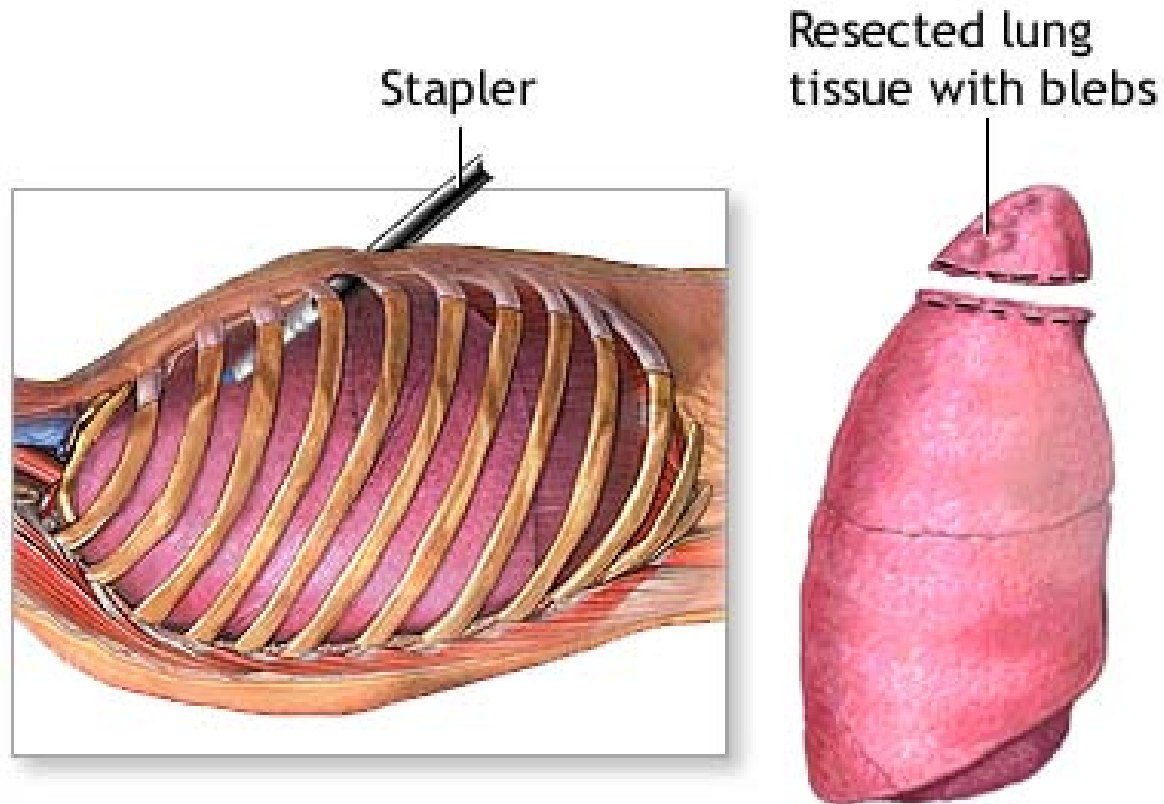


Terapia chirurgica-Vats- videotoracoscopia



ADAM.

Terapia chirurgica-Vats – apicectomia e pleurodesi



ADAM.